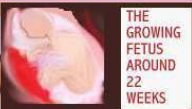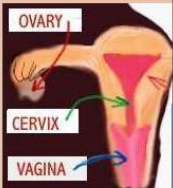

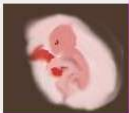
SIMPLIFYING MATERNAL NURSING

PART 2



THE
GROWING
FETUS
AROUND
22
WEEKS



ULTRASOUND



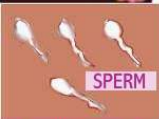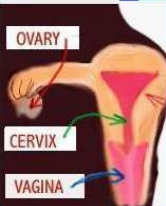
PART 2

LEARNING OBJECTIVES

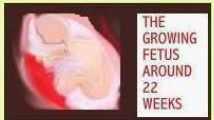
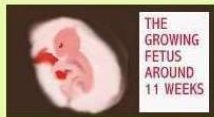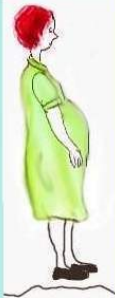- IDENTIFY THE STAGES OF THE GROWING FETUS
- IDENTIFY GRAVIDA, STRIAE NEGRA, STRIAE GRAVIDARUM
- RELATE FETAL ULTRASOUND AND FETAL HEART MONITORING
- IDENTIFY PLACENTA PREVIA AND CAUSES
- DISCUSS AMNIOCENTESIS
- DISCUSS PRETERM LABOR
- IDENTIFY PREECLAMPSIA AND MAGNESIUM SULFATE USED IN ITS TREATMENT



THE GROWING FETUS



CONCEPTION TAKES PLACE WHEN THE MALE SPERM AND FEMALE OVUM MEET. THIS USUALLY HAPPENS THROUGH SEXUAL INTERCOURSE, BUT MAY ALSO RESULT FROM OTHER METHODS SUCH AS IVF (IN VITRO FERTILIZATION).

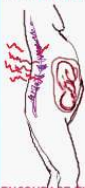

WHAT IS GRAVIDA?
GRAVIDA SIMPLY
MEANS A PREGNANT
WOMAN.

WHAT IS MULTI-
GRAVIDA?
MULTIGRAVIDA
SIMPLY MEANS A
WOMAN HAS BEEN
PREGNANT TWO OR
MORE TIMES.

PRIMIGRAVIDA- REFERS TO A WOMAN
WITH FIRST TIME PREGNANCY.

LOW BACK PAIN
MAY OCCUR
DURING PREGNANCY.



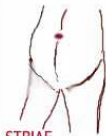ENCOURAGE THE USE
OF COMFORTABLE
FOOTWEAR.



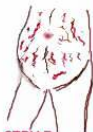THE SECOND AND THIRD TRIMESTER
MAY PRESENT DISCOMFORT FOR THE
MOTHER, AS THE FETUS CONTINUES
TO GROW. THE MOTHER SHOULD
BE ENCOURAGED TO MAINTAIN GOOD
POSTURE WHEN WALKING AND
STANDING. RESTING DURING THE
COURSE OF THE DAY IS ALSO VERY
HELPFUL.



ELEVATION OF THE LOWER LEGS
WILL ALSO HELP TO DECREASE
SWELLING.

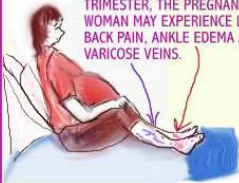

STRIAE
NEGRA

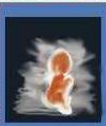
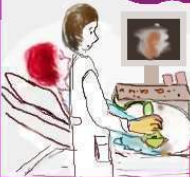
STRIAE
GRAVIDARUM
(STRETCH
MARKS)

DURING THE SECOND AND THIRD
TRIMESTER, THE PREGNANT
WOMAN MAY EXPERIENCE LOW
BACK PAIN, ANKLE EDEMA AND
VARICOSE VEINS.



FETAL ULTRASOUND



FETAL ULTRASOUND AT 12 WEEKS.



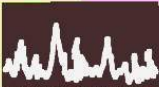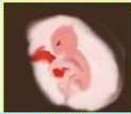DURING PREGNANCY, THE DOCTOR MAY ORDER A FETAL ULTRASOUND. THIS TEST MAY BE DONE FOR A NUMBER OF REASONS. INFORMATION THAT MAY BE OBTAINED

MRS. L IS HAVING A FETAL ULTRASOUND DONE. THE TECHNICIAN APPLIES CONTACT GEL TO THE SKIN AND THEN USES A PROBE TO SENSE THE SOUND WAVES, SIMILAR TO WHAT BOATS USE TO VIEW THE OCEAN'S FLOOR. ULTRASOUND WAVES ARE USED TO DIAGNOSE INTERNAL STRUCTURES LIKE THE GROWING FETUS.

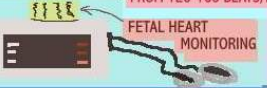FROM AN ULTRASOUND INCLUDE:

- NUMBER OF BABIES IN UTERO
- ECTOPIC (TUBAL) PREGNANCY
- CONGENITAL ABNORMALITIES
- ANY BLEEDING IN UTERO
- FETAL HEART RATE AND MOVEMENT.

AS EARLY AS 12 WEEKS, THE FETUS IS SENSITIVE TO THE ABDOMEN BEING PRESSED AND HAS NERVE REFLEXES. ULTRASOUND IS CONSIDERED TO BE SAFE.



NORMAL FHR MAY RANGE FROM 120-160 BEATS/MIN.



FETAL HEART MONITORING

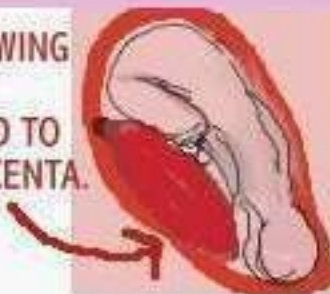
AN ELECTRICAL FETAL MONITOR IS USED TO RECORD THE BABY'S HEART RATE.



BELTS ARE STRAPPED AROUND THE ABDOMEN AND SENSORS ARE HELD IN PLACE, TO MONITOR FETAL HEART RATE (FHR) AND UTERINE CONTRACTIONS. INFORMATION IS RECORDED ON PAPER.

PLACENTA PREVIA

THE GROWING FETUS IS ATTACHED TO THE PLACENTA.



PAINLESS VAGINAL BLEEDING MAY OCCUR SUDDENLY.

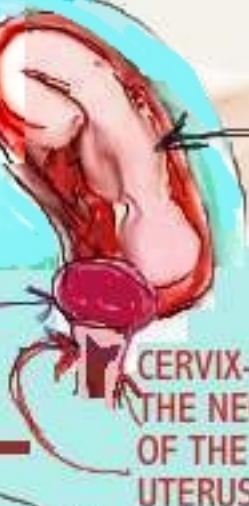

BLEEDING MAY RANGE FROM MILD TO HEAVY.




CAUSES INCLUDE:-
-SMOKING IN PREGNANCY
-PREVIOUS C-SECTION
-HISTORY OF MANY PREVIOUS PREGNANCIES

GROWING FETUS

THE PLACENTA DEVELOPS IN THE BOTTOM OF THE UTERUS



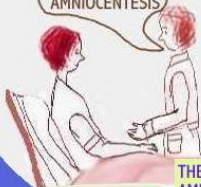FETAL HEART MONITORING



ULTRASOUND IS USED TO CONFIRM DIAGNOSIS OF PLACENTA PREVIA. C-SECTION MAY OR MAY NOT BE NECESSARY.

AMNIOCENTESIS

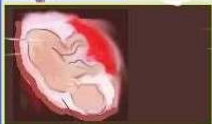I WOULD LIKE
TO DO AN
AMNIOCENTESIS



AMNIOCENTESIS IS A DIAGNOSTIC TEST THAT IS GENERALLY DONE AROUND 15-20 WEEKS OF PREGNANCY, TO DETERMINE IF THERE ARE ANY BIRTH DEFECTS. THE BABY'S SEX CAN ALSO BE DETERMINED.

AMNIOCENTESIS ALSO PROVIDES INFORMATION ABOUT CHROMOSOMES, DOWNS SYNDROME AND SICKLE CELL ANEMIA.

THE DOCTOR DISCUSSES
AMNIOCENTESIS WITH MRS. L.



SICKLE CELL ANEMIA AND DOWNS SYNDROME MAY BE DETECTED WHEN AMNIOCENTESIS IS PERFORMED.

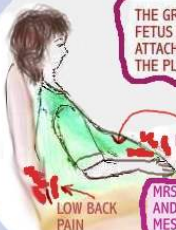A SMALL AMOUNT OF AMNIOTIC FLUID IS REMOVED FROM THE UTERUS VIA A NEEDLE AND SYRINGE.

SICKLE
SHAPED
RED BLOOD CELLS

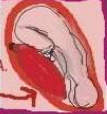NORMAL RED
BLOOD CELLS

SICKLE CELL ANEMIA

PRETERM LABOR



THE GROWING FETUS IS ATTACHED TO THE PLACENTA.



MILD ABDOMINAL CRAMPS

LOW BACK PAIN

THE NURSE TAKES A HISTORY FROM MRS.S.



MRS.S CAN YOU TELL ME WHEN IS YOUR DUE DATE

ADMISSION TO THE HOSPITAL FOR FURTHER MONITORING IS DONE.

MRS.S IS 28 YEARS OLD AND IN HER SECOND TRIMESTER OF PREGNANCY.

QUICK INTERVENTION IS NEEDED FOR THE PATIENT IN PRETERM LABOR. SLOWING THE PROCESS OF LABOR IS A PRIORITY.

MAGNESIUM SULFATE (Tocolytic Medication) OR STEROIDS MAY BE USED TO TREAT PRETERM LABOR.

Q- WHAT IS PRETERM LABOR?
A- PRETERM LABOR IN SIMPLE TERMS, IS LABOR THAT BEGINS BEFORE THE EXPECTED DATE OF DELIVERY. IT MAY HAPPEN IN THE FIRST, SECOND OR THIRD TRIMESTER OF PREGNANCY.

SYMPTOMS INCLUDE:

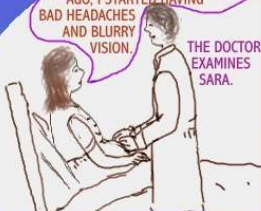- LOW BACK PAIN
- MILD UTERINE CONTRACTIONS
- ABDOMINAL CRAMPS LIKE MENSTRUAL CRAMPS
- VAGINAL BLEEDING OR WATERY DRAINAGE (WHICH MAY BE CAUSED BY "WATER BREAKING"
- FATIGUE

CAUSES OF PRETERM LABOR INCLUDE:

- STRESSFUL EVENT
- TRAUMA, INFECTION
- A VERY STRETCHED UTERUS FROM PREVIOUS PREGNANCIES
- UTERINE BLEEDING OR PLACENTAL SEPARATION

PREECLAMPSIA

DR. I FEEL AWFUL. THREE DAYS AGO, I STARTED HAVING BAD HEADACHES AND BLURRY VISION.



THE DOCTOR EXAMINES SARA.

SARA IS IN HER SECOND TRIMESTER (24 WEEKS). SHE HAS PREECLAMPSIA.

SIGNS AND SYMPTOMS INCLUDE:

- SEVERE HEADACHE
- BLURRY VISION
- NAUSEA, VOMITING
- DECREASE IN URINARY OUTPUT
- HYPERTENSION (HIGH BLOOD PRESSURE)
- PROTEINURIA (LARGE AMOUNTS OF PROTEIN IN THE URINE)



IF MAGNESIUM IS USED, CLOSE MONITORING OF THE RESPIRATORY AND NEUROLOGICAL STATUS SHOULD BE DONE

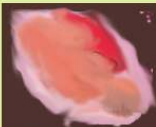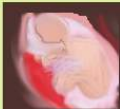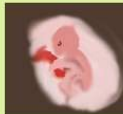HYPOREFLEXIA- DECREASE IN



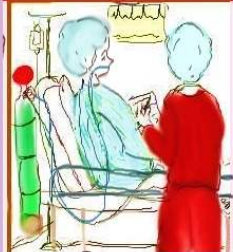
TYPICALLY, PREECLAMPSIA OCCURS AFTER THE 20TH WEEK OF PREGNANCY (DURING THE SECOND TRIMESTER). THE CAUSE OF THIS CONDITION IS NOT FULLY UNDERSTOOD. IT MAY BE TRIGGERED BY HYPERTENSION OR PROBLEMS ASSOCIATED WITH CIRCULATION.

MAGNESIUM SULFATE INFUSION IS USED TO TREAT PREECLAMPSIA. SIDE EFFECTS SUCH AS:- RESPIRATORY DEPRESSION, ALTERED MENTAL STATUS AND DECREASE IN TENDON REFLEXES MAY RESULT FROM MAGNESIUM INFUSION. CALCIUM GLUCONATE IS THE ANTIDOTE USED FOR MAGNESIUM SULFATE.

THE
GROWING
FETUS
AROUND
11 WEEKS



ABRUPTIO PLACENTA



PART 3 TO
FOLLOW